


PATIENT

 Mittens 680 Animal
 Rescue

SPECIES

Feline

BREED

DSH

SEX

Male

AGE

5 months

WEIGHT

6.6lbs

INTERPRETED BY

 Maggie Machen Lamy,
 DVM, DACVIM
 (Cardiology)

IMAGING PERFORMED BY

 Mark van Campen,
 DVM

HOSPITAL NAME

 Mississippi Mills
 Animal Hospital

REFERRING VET

Dr. van Campen

INVOICE

24807

DATE

6/15/22

PRESENTING CLINICAL SIGNS

History: Grade V/VI heart murmur.

ECHOCARDIOGRAM FINDINGS

2D, m-mode, color flow and doppler imaging is available. The left ventricular wall is normal in dimension. The LV chamber is normal. A small diameter perimembranous VSD is seen just below the aortic valve. The shunt is left to right. No obvious right to left flow identified. The left atrium is mildly increased in size. The right atrium is normal in size. A small ASD is seen on color flow imaging. The right ventricle appears normal. The MPA is mildly dilated. The mitral valve is normal in structure and mobility. No MR. Blood flow through the LVOT is normal in velocity. Blood flow through the PV is mildly elevated in velocity due to relative pulmonic stenosis. No PI. There is no pleural or pericardial effusion seen. No additional shunts or abnormalities are visualized.

CARDIAC CHART

FELINE CARDIAC PARAMETERS	BODY WEIGHT (kg)	HR (BPM)	IVSd (cm) (Moise, Pipers)	LVIDd (cm) (Moise, Pipers)	LWVd (cm) (Moise, Pipers)	FS (%)	EF (%)
NORMAL PARAMETER	-----	150-240	0.35-0.55	<2 (mean 1.5)	3.5-0.55	35-67	80-100
PATIENT	2.99	NM	0.40	1.4	0.42	54	90
FELINE CARDIAC PARAMETERS	LA/AO (Boon)	LA/AO HEART BASE (Swe) (Abbott)	LA 2D short axis Base view (cm) (Abbott)		LVOT VEL (m/s)	RVOT VEL (m/s)	E max (m/s)
NORMAL	<1.5	<1.3	<1.2		<1.6	<1.3	<0.9
PATIENT	NM	1.4	1.3		1.7	2.5	NM

**Note: All measurements based upon multi-modal images and methods. An average value is reported.*
 Adapted from June Boon, Veterinary Echocardiography, 1998
 Abbott J & MacLean H JVIM 2006;20: 111-119, Moise et al. Am J Vet Res 47:1476, 1986. Pipers et al. Am J Vet Res 40:882, 1979.

INTERPRETATION OF THE FINDINGS & FURTHER RECOMMENDATIONS

The cause of the murmur is a perimembranous ventricular septal defect (VSD). The defect is relatively small in dimension, with high velocity left to right flow. There is evidence of mild LA enlargement, which is concerning in a 5-month-old cat. The MPA is mildly dilated, supporting mild volume overload/relative PS. A small ASD is also seen, with flow shunting from the left to right atrium. This is hemodynamically insignificant at this time; however, follow up is advised. No additional congenital defects are visualized. Given the location of the defect, arrhythmias should be monitored for lifelong through periodic auscultation and ECG monitoring.

VSDs in cats have variable outcomes, and lifelong monitoring is advised. The defect in this case appears hemodynamically significant, leading to increased concern for volume overload over time and potentially progression to clinical signs and development of CHF within the patient's lifespan. The prognosis is guarded however, as the rate of progression with subclinical cardiomyopathy is highly variable. Patient will always remain at risk for development of congestive signs, arrhythmias and/or sudden death in the future.



PATIENT

Mittens 680 Animal
Rescue

With only mild heart enlargement, use of medications is not yet recommended. This may change in the future should further volume overload be noted.

SPECIES

Feline

Anesthetic risk is considered mild at this time, however judicious IV fluid rates are advised to avoid fluid overload. Additionally, drugs that stimulate heart rate should be avoided unless clinically necessary (glycopyrrolate, atropine). A reasonable protocol includes opioid/benzodiazepine premedication, propofol induction, isoflurane maintenance.

BREED

DSH

Monitor at home for any associated clinical signs, including respiratory changes or signs of a thrombus.

SEX

Male

PLAN
No medications are indicated at this time.

AGE

5 months

Recommend a recheck echocardiogram and ECG in 6-12 months to screen for progression.

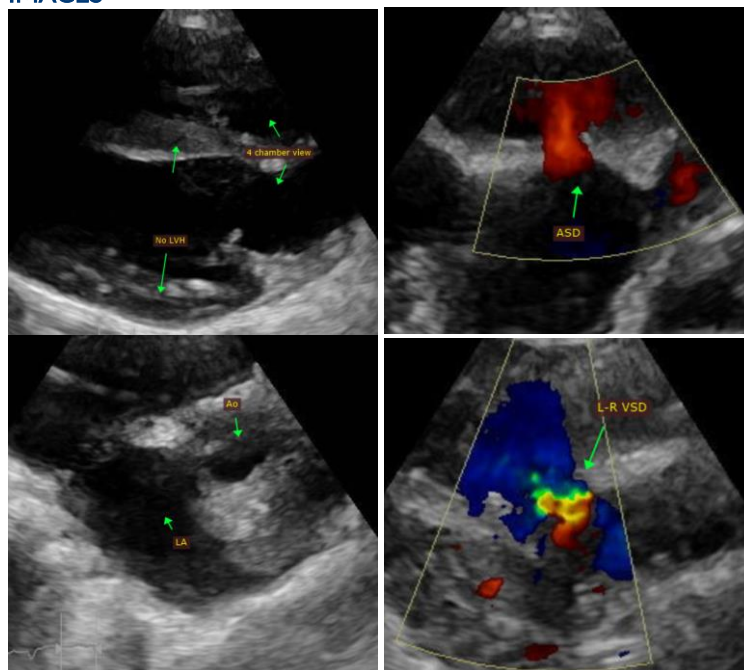
WEIGHT

6.6lbs

IMAGES

INTERPRETED BY

Maggie Machen Lamy,
DVM, DACVIM
(Cardiology)



IMAGING PERFORMED BY

Mark van Campen,
DVM

HOSPITAL NAME

Mississippi Mills
Animal Hospital

REFERRING VET

Dr. van Campen

The information and recommendations provided are based on the images presented by the referring veterinarian. No evaluation can be communicated regarding pathology that was not visible in the image/video clips provided.

INVOICE

24807

Thank you for this referral. This report was generated using transcription software, and minor dictation errors may be present. If the clinical or image interpretation does not parallel your findings or if I can be of any further assistance, please contact me.

DATE

6/15/22

Maggie Machen Lamy, DVM
Diplomate of the American College of Veterinary Internal Medicine (Cardiology)
info@sonopath.com